

Ridge Preservation Using Composite Alloplastic Materials: A Randomized Control Clinical and Histological Study in Humans

Yaniv Mayer, DMD;* Hadar Zigdon-Giladi, DMD;† Eli E. Machtei, DMD‡

ABSTRACT

Aim: To evaluate (clinically, histologically, and histo-morphometrically) the use of composite materials (Biphasic calcium sulphate [BCS] with β Tri-Calcium Phosphate (β -TCP) and Hydroxyapatite [HA]) in extraction socket sites and compare it to un-disturbed natural healing.

Material and Methods: Prospective clinical trial of 36 patients (40 extraction sockets) were randomly assigned to either test or control group. Alveolar ridge horizontal dimension was measured in the middle of the socket at crest and 3 and 6 mm subcrestally. Crestal vertical height was measured at baseline surgery and at 4 month re-entry, at which time bone core biopsies were harvested from the center of the edentulous ridge. Histo-morphometric evaluation of the samples was performed using hematoxylin & eosin stains and morphometric software.

Results: The change in horizontal ridge width was higher in the control compared to the experimental group: 2.28 ± 2.36 mm versus 0.03 ± 2.32 mm ($p = .007$) at -3 mm and 2.28 ± 2.43 versus 0.035 ± 3.05 ($p = .02$) at -6 mm, for the experimental and control sites, respectively. The vertical distance from bone crest to neighboring horizontal line interconnecting the neighboring teeth was minimal in both groups (0.307 ± 2.01 mm versus 0.14 ± 2.03 mm [$p = 0.41$]). Residual scaffolds occupied $15.99 \pm 11.4\%$ of the volume in the grafted (test) sites while bone area fraction was not statistically different among the groups ($47.7 \pm 10.6\%$ versus $52.6 \pm 11.6\%$, test versus control, respectively $p = .39$). The percentage of connective tissue in the control group was significantly higher than test group ($36.3 \pm 19.4\%$ versus $46.7 \pm 10.6\%$ test versus control, respectively, $p = .013$).

Conclusion: Ridge preservation technique using a combination of two synthetic bone grafts β -TCP and HA with BCS resulted in greater stability in the horizontal dimension after 4 months.

KEY WORDS: alloplast, beta TCP, bi phasic calcium sulphate, bone regeneration, bone resorption, socket preservation

INTRODUCTION

The ultimate goal of implant dentistry is to restore missing teeth by placing implants in anatomically, esthetically, and functional restorative positions.¹ To this end, the challenge facing the dental team is associ-

ated with extraction site wound healing that is characterized by rapid bone resorption at this site.^{2,3} This in turn may result in esthetic and restorative challenges associated with the reduce bone volume available for implant placement. Most of the alveolar changes in extraction socket occur during the first year after tooth extraction with two thirds of the bone loss occurring on the buccal aspect. The apico-coronal bone height may be reduced by approximately 0.8 mm after 3 months of healing while after 12 months these negative changes may reach 2 mm; the changes in the horizontal dimensions are usually greater (up to 4–5 mm during the first year).^{4,5} Several studies which have investigated the reasons for the morphologic alternations concluded that the loss of bundle bone may be involved in these changes.^{6–8}

*Doctor, School of Graduate Dentistry, Department of Periodontics, Rambam Health Care Campus, Haifa, Israel; †Associate Professor, Head of Lab of Bone Regeneration, School of Graduate Dentistry, Department of Periodontics, Rambam Health Care Campus, Haifa, Israel; ‡Professor, Head of the School of Graduate Dentistry, Department of Periodontics, Rambam Health Care Campus, Haifa, Israel

Corresponding Author: Dr. Yaniv Mayer, Department of Periodontics, School of Graduate Dentistry, Rambam Health Care Campus, P.O. Box 9602, Haifa 31096, Israel; e-mail: dr.yaniv.mayer@gmail.com

© 2016 Wiley Periodicals, Inc.

DOI 10.1111/cid.12415

To reduce the rate of the alveolar ridge dimensional changes, different grafting materials were used in fresh extraction sockets and bone volume and linear dimensional changes were tracked. Recently, Ten Haggeler and colleagues in a systematic review were able to show that the use biomaterials placed into the socket immediately after extraction contributed significantly to the preservation of the alveolar ridge volume during healing.⁹

Bone grafts have long been used in reconstructive surgery with the aim of increasing the bone volume in the previous defect area. Alloplastic bone graft has osteoconductive properties and is relatively safe and cost effective. Another important advantage of using synthetic materials (over autogenous bone graft) is the lower morbidity associated with the augmentation procedure and would represent an important step forward in simplifying bone regeneration techniques.

One of these alloplastic materials is calcium sulfate (CS) which has enjoyed a longer history of clinical use than most currently available biomaterials. It is well tolerated when used to fill bone defects and undergoes rapid and complete resorption. CS possesses many of the characteristics required from materials for bone regeneration and, therefore, was widely used in many regenerative procedures including periodontal regeneration, sinus augmentation, extraction socket preservation, and for bone regeneration associated with dental implant placement.^{10–13} The mechanisms by which CS enhances bone formation have not been completely elucidated. It has been suggested that CS particles bind to adjacent bone and then resorbed, providing a mechanism to guide and enhance new bone growth.¹⁴ Despite its many virtues, it does have some shortcomings, mainly its rapid and complete resorption which is both a virtue and vice.

A recently introduced biphasic calcium sulfate (BCS) has shown to be more stable with better handling properties than CS. BCS is an innovative granulated powder form. Once it encounters saline, the granulated powder goes through a rapid and efficient setting. This setting allows the in situ formation of a rigid structure which is highly crystalline, despite the interfering harsh environment (blood, proteins, and saliva).

Biphasic calcium phosphate (BCP), an intimate mixture of hydroxyapatite (HA) and beta-Tricalcium phosphate (β -TCP), was proposed in dentistry as ref-

erence for synthetic materials. It offers great potential for bone reconstruction since it has a chemical composition similar to that of biological bone apatites.¹⁵ BCP has already proven its efficiency as bone substitution material in different human clinical applications^{16–18}; however, there are only few published clinical studies with long term follow-up.

In the present study, we set to examine the benefit of combining the above two alloplastic materials (BCP plus BCS) to benefit from the unique characteristic of each material and to create an optimal bone regeneration material in extraction socket. As the resorption kinetics of the two materials is different, we believed that the combination of these two materials may create a scaffold with mechanical integrity which maintains its volume while creating a unique microarchitecture with different pore sizes which may facilitate condition for blood vessels growth.

To do so, we have evaluated clinically, histologically, and histomorphometrically the use of composite allograft materials (BCS and BCP) in extraction socket sites and compare it to the natural socket healing process after tooth extraction in human.

MATERIAL AND METHODS

Study Population and Design

The research was initially approved by the institutional IRB (Helsinki committee) and conducted from January 2012 to December 2013. The nature of the study was conveyed and informed consent was obtained from all subjects prior to commencement.

Subjects requiring tooth extraction at the department of periodontology Rambam HCC were approached to participate in the study. Those patients that have consented to participate were enrolled into this prospective clinical trial. To be included patients had to be 18 years or older with at least one tooth scheduled for extraction and subsequently scheduled for an implant-supported restoration. Subjects were excluded if they had one or more of the followings: (i) history of systemic disease that would contraindicate oral surgical treatment; (ii) long-term nonsteroidal anti-inflammatory drug therapy exceeding 100 mg daily; (iii) intravenous and oral bisphosphonate therapy; (iv) pregnant or lactating women; (v) unwillingness to return for the follow-up examination; (vi)

smokers (>10 cigarettes per day); (vii) Acute dento-alveolar infection.

Subjects were randomly assigned to either the test group (T) where a composite BCS/BCP was placed in the socket following extraction or to the control group (C) in which the sockets were left to heal with no grafting material. The randomization algorithm accounted for tooth position, arch, and smoking status. The operator was informed of the group allocation only after the tooth extraction.

Surgical Procedure

After administration of local anesthesia, a sulcular incision was performed and muco-periosteal flaps were raised around the nonrestorable teeth. The tooth was carefully and gently luxated using a periostat. To ensure a-traumatic extraction, the roots of molar teeth were separated by a fine straight bur before luxation with a periostat. Extraction of the luxated tooth was performed with surgical forceps to minimize the amount of mechanical pressure applied to the buccal bone. The extraction sockets were debrided and granulation tissue was removed. Clinical measurements and records were taken as follows: the horizontal dimension of the socket was measured with a dental caliper (3M™ ESPE™ MDI Ridge Mapping Calipers) at three heights from the crest: 0, 3, and 6 mm. The vertical distance was measured from the most coronal part of the ridge to a reference point on neighboring tooth (cemento-enamel junction [CEJ] or the prosthetic crown margins) with a standardized periodontal probe (Williams, Hu- Friedy, Chicago IL, USA).

A 1:1 mixture of BCP (4BONE, Biomatlante ZA les Quatre Nations, France) and BCS (BOND BONE, MIS Implant Technologies Ltd., Israel) was used as the grafting material in the T group. The extraction sockets were filled and slightly condensed. The surgical protocol for the control group patients was similar to the test group except that the extraction socket was not grafted.

Next, two parallel vertical incisions were made beyond the muco-gingival junction (MGJ); the buccal flaps were coronally advanced to achieve primary closure and secured with the 5/0 Nylon suture material. Patients were instructed not to brush the surgical sites for 1 week. Systemic Amoxicillin (500 mg three times a day for 7 days) was prescribed and subjects were instructed to rinse with 0.2% chlorhexidine gluconate

mouth-rinse twice daily for 2 weeks. The patients received ibuprofen (400 mg three times a day for the first day) to manage postsurgical discomfort and inflammation. Patients allergic to amoxicillin were prescribed clindamycin 300 mg bid. Sutures were removed 14 days postoperatively.

Reentry Procedure and Bone Biopsy

Four months after extraction a muco-periosteal flap was elevated in the former socket site. The dimensions of edentulous ridge were measured and recorded (as described in surgical procedure section). Next, bone core biopsies (8–10 mm length and 2 mm in diameter) were harvested from the center of the edentulous ridge using a trephine drill. The bone biopsy was transferred immediately into 4% buffered formalin. Subsequently, dental implant was inserted after final preparation of the osteotome. Subject received the same drug prescription as after the initial surgery. The bone cores were coded and sent for analysis at the bone research laboratory in our center.

Histological Processing

All biopsies were fixed in 4% paraformaldehyde for 2 days and decalcified in 10% EDTA, (Sigma-Aldrich, MS, USA) for 4 weeks, cut into two halves in the midline, embedded in paraffin, and sectioned (8 μ m). For determination of bone morphology, sections were stained with Masson's trichrome and Hematoxylin and Eosin (H&E).

Histomorphometric Analysis

Histomorphometric evaluation of the samples was performed on two nonconsecutive sections from each specimen, under a light microscope (Zeiss Axioskop, Carl Zeiss, Jena, Germany) using software (image j) for image analysis. The following values were measured: (i) total bone area (ii) connective tissue (iii) residual bone graft. The measurements were expressed as percentages of the total sample area.

Statistical Analysis

To compare baseline and final measurement a two tailed paired Student's *t*-test was used. To compare changes (baseline to reentry) between the T and C groups we used un-paired student *t*-test.

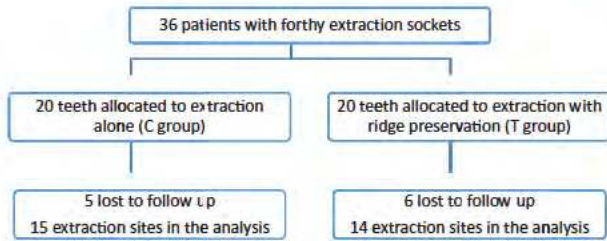


Figure 1 Flow diagram reports the number of participants, the number of extraction sites assigned to treatments, the follow-up period, and the number of sites in the analysis.

A p value $< .05$ was selected to determine statistical significance with the Bonferroni correction for multiple comparisons.

RESULTS

Thirty-six patients enrolled in this study (23 females, 13 males) contributed 40 sites of extraction. Five patients in the control group and six patients in the test group were lost during follow-up. Figure 1 describes the distribution of the extracted teeth in the T & C.

Table 1 describes the distribution of extracted teeth among the study groups: 14 premolar and molar teeth were enrolled in the test group, (6 in the maxilla and 8 in the mandible). In the control group, 12 teeth were in posterior area and three in the anterior segments (6 in the maxilla and 9 in the mandible). All the surgical procedures and consequent follow-up were conducted without any significant complication. Four months (117 ± 1.94 days, 119 ± 1.32 days, test and control, respectively) after the extraction an implant was inserted.

Dimensional Ridge Changes

Horizontal and vertical changes are represented in Tables 2 and 3. At baseline, the test group had horizontal ridge width of 8.3 ± 3.3 mm, 9.5 ± 3.7 mm, 10.3 ± 3.5 mm at 0 mm, -3 mm, and -6 mm (from the crest), respectively. These values were not statistically different from the control group at baseline measurement. At re-entry, only minimal and not

TABLE 2 Horizontal Ridge Width (Mean \pm SD) at Baseline and the Change

Group	0 mm	-3 mm	-6 mm
Test (baseline)	8.3 ± 3.3	9.5 ± 3.7	10.3 ± 3.5
Control (baseline)	6.6 ± 4.3	9.3 ± 3.0	10.0 ± 2.9
<i>p</i> -Value	.56	.23	.2
Δ Test	-0.96 ± 2.63	0.03 ± 2.32	-0.035 ± 3.05
Δ Control	-1.33 ± 2.25	-2.28 ± 2.36	-2.28 ± 2.43
<i>p</i> -Value	.35	.007	.02

significant bone resorption was measured in the test group. Changes in horizontal ridge width were: 1.1 mm, 0.5 mm, and 0.1 mm at 0 mm, -3 mm, and -6 mm, respectively. Contrary, in the control group horizontal bone loss was observed amounting to 0.8, 1.8, and 2.6 mm, or these three sites. Differences in the horizontal dimensions (baseline to 4 months) were significant at all three points in the control group: At -3 bone loss was 2.28 mm for the control with negligible bone gain (0.03 mm) in the test group ($p = .007$). At -6 bone loss was 2.28 mm for control with negligible bone loss (0.035 mm) in test group ($p = .02$).

The vertical distance (bone crest to the horizontal line connecting the CEJ of the neighboring teeth) was similar among the two groups at baseline and were basically unchanged at the final re-entry measurements (Table 3).

Histologic Evaluation

Control Sites. All biopsies harvested from the natural healing sockets reveal vital bone formations. Concentric lamellar structures and Haversian canals were observed, suggesting the presence of mature lamellar bone (Figure 2). The trabecular spaces were filled by loose connective tissue with thin vessels (Figure 3).

Test Sites. Bone biopsies from ridge preservation sites did not reveal any inflammatory response or fibrous encapsulation of the alloplastic bone particles. All

TABLE 1 Distribution of the Extracted Teeth Among the Study Groups

Group	Incisor	Canine	Premolar	Molar	Maxilla/	
					Mandible	Total
Test	0	0	6	8	6/8	14
Control	1	2	4	8	6/9	15

TABLE 3 Δ Vertical Ridge Measurements at Baseline and at Re-entry (Mean \pm SD)

Group	Initial	4 months	Δ mm	<i>p</i> -Value
Test	5.04 ± 2.05	5.11 ± 2.70	0.307 ± 2.01	.59
Control	5.4 ± 2.1	5.3 ± 1.6	0.14 ± 2.03	.56
<i>p</i> -Value	.79	.76	.41	

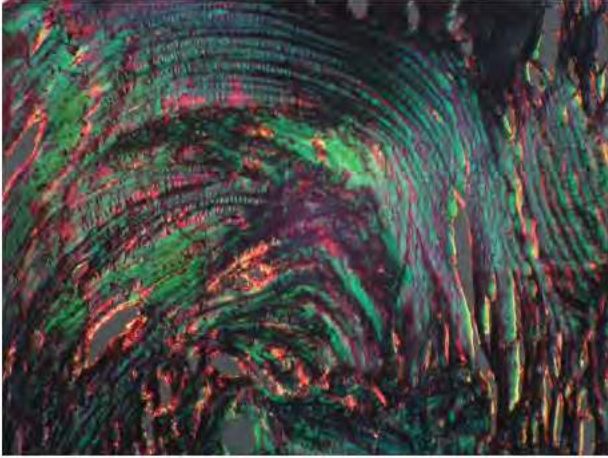


Figure 2 Polarized light microscope demonstrate the presence of lamellar bone 4 months following extraction, indicating final stage of bone maturation.

sections showed bone formation adjacent to residual graft particles (Figure 4). Moreover, osteoclastic – mediated graft resorption was detected. Similar to control specimens, newly formed bone presented characteristics of mature lamellar bone.

Histomorphometric Analysis

The results of the histomorphometric analysis are shown in Table 4. No significant differences were found between the two groups in respect of the total bone area. However, in the control group more connective tissue was noticed. ($46.7\% \pm 10.6$ versus $36.3\% \pm 19.4$, $p = .03$).

DISCUSSION

In the present randomized control clinical study, the use of this composite alloplastic material for ridge

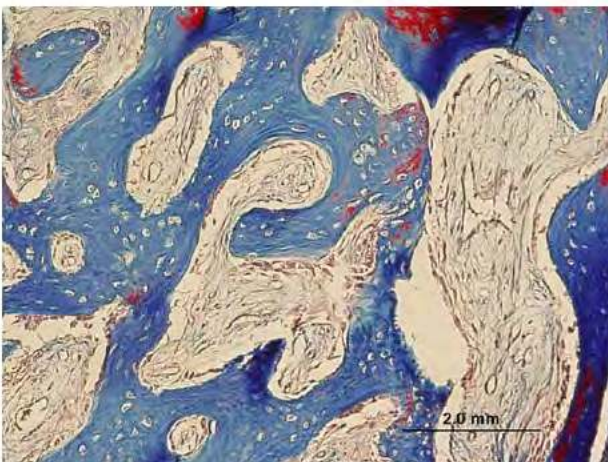


Figure 3 Representative image of control group demonstrating the trabecular spaces were filled by loose connective tissue with thin vessels. (Masson trichrome).

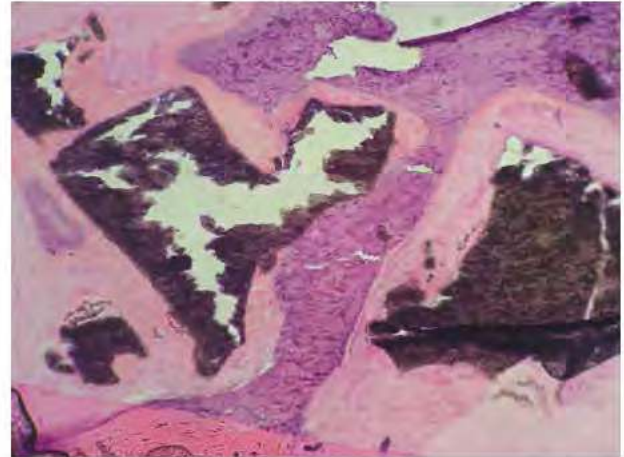


Figure 4 Representative image of test group demonstrating residual scaffold, surrounded by new bone and connective tissue (H&E).

preservation reduced post extraction bone resorption and allowed new bone formation without causing significant inflammatory response.

Previous studies investigated soft and hard tissue dimensional changes following ridge preservation using various bone grafts and bone substitutes including: allografts, xenografts, and autologous bone. Nevertheless, choosing the ideal grafting material is still a challenging task. An ideal bone substitute should be biocompatible, osteoconductive, and osteoinductive, easy to shape and manipulate safe and bioresorbable. Biphasic calcium-phosphates meets all these criteria: it's structure and chemical composition is very similar to that of hydroxy appetite¹⁹⁻²³; it is biocompatible, osteoconductive and possesses osteoinductive properties²⁰⁻²³; it possesses appropriate porosity for vascular invasion and nutrient diffusion from surrounding tissue and has surface chemistry to allows cells to adhere and express osteogenic phenotype.²⁰⁻²³ It is characterized appropriate mechanical properties; it is synthetic and cost effective, is able to form a suitable shape easily, and ultimately replaces the bone within a short period.¹⁹⁻²³ The addition of BCS improves the

TABLE 4 Histomorphometric Analysis (% Total Sample Area, Mean \pm SD)

Group	Total Bone Area	Connective Tissue	Residual Graft
Test	47.7 ± 10.6	36.3 ± 19.4	15.99 ± 11.4
Control	52.6 ± 11.6	46.7 ± 10.6	NA
p-Value	.76	.03	—

handling characteristics of BCP by acting as a binder between HA and TCP particles. Furthermore, the rapid resorption of BCP leaves porosity that would enhance the ingrowth of bone.²⁴

A recently published meta-analysis evaluated bone dimensional changes following ridge preservation procedures and the influence of several variables of interest on the outcomes of ridge preservation therapy.²⁵ They found that alveolar ridge preservation is effective in limiting physiologic ridge reduction as compared with tooth extraction alone. The clinical magnitude of the effect was 1.89 mm in terms of bucco-lingual width. A recent systematic review conducted by Horowitz and colleagues demonstrated that there appears to be supporting ridge preservation techniques as a whole; without significant difference among various grafting materials.²⁶ To the contrary, other studies did not find advantage in terms of bone fill and bone composition following ridge preservation technique in comparison to natural bone healing. They concluded that the bone graft materials only served as a scaffold and did not stimulate new bone formation.^{27,28} In accordance with these results, in the present study extraction sites that were filled with BCP/BCS showed no reduction in bucco-lingual width compared with 2.28 ± 2.36 mm in the control (extraction alone) sites. While most of the data concerning alveolar ridge dimensional changes is based on teeth in the nonmolar region,^{2,3} in the present study, 14/14 sockets in the test group, and 12/15 socket in the control group were in the premolar and molar sites. This fact may influence the magnitude of bone loss. The buccal plate in the anterior region is usually thin²⁷ thus ridge alterations in the alveolar dimension are more likely to occur in these sites.^{29,30}

According to Avila-Ortiz and colleagues, vertical ridge changes of 1.18 to 2.07 mm are to be expected in midbuccal and midlingual height, and 0.24 to 0.48 mm for mesial and distal height changes. Indeed, vertical measurements in the current study were taken in the midbuccal and midlingual aspects using the neighboring tooth CEJ as reference. Our results showed only minimal changes in vertical bone height in both the control and test groups. These results can be attributed to the presence of bone and PDL in adjacent tooth that is responsible for maintaining blood supply to the alveolar bone thus helping to preserve bone height at these sites. Moreover, the neg-

ligible vertical bone loss we found in both groups can be accredited to the surgical procedure we performed. In all extraction sites (test and control groups), two parallel vertical incisions were made beyond the MGJ and the buccal flaps were coronally advanced to achieve primary closure. A recent meta-analysis conducted by Vignoletti and colleagues showed that extraction procedure involved flap elevation had significantly less horizontal bone loss when compared to flapless extraction.³¹ The authors explained this finding by the primary intention healing which achieved by the flap reflection. Still most of the clinicians to date do not attempt to achieve primary closure due to conflicting studies and concern about chair time, healing time and morbidity.³²

This study has some limitations in terms of the relatively small sample size and patient drop out during follow-up. Moreover, the study could have benefited from an additional two control groups: BCS and BCP separately. Although the harvesting of bone sample with trephine is a common method, it may affect the histologic specimens near the samples' borders. Therefore, for the purpose of this study only used sections from the middle of the core biopsy.

Evaluating the nature of healing following ridge preservation procedures demands harvesting a core biopsy and histological analysis. In the present study, mature lamellar bone was observed in both test and control specimens. Characteristics of vital bone including adequate neovascularization as well as osteocytes within the lacunae were found in all samples. Active bone remodeling was detected by the presence of osteoclasts and reversing lines. Importantly, inflammatory signs were not found. Percentage of bone fill, residual scaffold and connective tissue differ among studies and depend on various parameters: surgical procedure, material that was used to fill the socket and healing period. Toloue and colleagues compared clinically and histology bone healing following ridge preservation using CS and freeze-dried bone allograft (FDBA).³³ Histological analysis (3 months following ridge preservation) revealed an average of 32% new bone formation with 2.5% graft remaining for the CS group and 16.7% new bone formation with 21% of the graft remaining for the FDBA. Moreover, clinical measurements found nonsignificant changes in vertical dimensions and similar bucco-lingual bone resorption in both groups. Additional study by Kumari and

colleagues, compared clinically and histologically nanocrystalline CS bone grafts and medical-grade CS bone grafts in human extraction sockets. Higher percentage of new bone formation was reported (~50%) and residual graft was approximately half compared to our finding (~7%).³⁴

CONCLUSION

The results of this prospective clinical trial show that ridge preservation technique using a combination of two synthetic bone grafts (β -TCP and Hydroxyapatite HA with BCS) is superior to natural healing process in terms of horizontal dimensional changes after 4 months. Moreover, according to histological analysis, percentage of residual graft was relatively small without evidence for inflammatory response or graft encapsulation.

CONFLICT OF INTEREST STATEMENT

The authors declare that they do not have conflict of interest regarding the present study. The study was partially supported by an educational grant from the MIS implants technology.

REFERENCES

- Shenoy VK. Single tooth implants: pretreatment considerations and pretreatment evaluation. *J Interdiscip Dent* 2012; 2:149–157.
- Van der Weijden F, Dell'Acquie F, Slot DE. Alveolar bone dimensional changes of post extraction sockets in humans: a systematic review. *J Clin Periodontol* 2009; 36: 1048–1105.
- Tan WL, Wong TL, Wong MC, Lang NP. A systematic review of post extractional alveolar hard and soft tissue dimensional changes in humans. *Clin Oral Implants Res* 2012; 23(Suppl 5):1–21.
- Irinakis T. Rationale for socket preservation after extraction of a single-rooted tooth when planning for future implant placement. *J Can Dent Assoc* 2006; 72:917–922.
- Schropp L, Wenzel A, Kostopoulos L, Karring T. Bone healing and soft tissue contour changes following single tooth extraction: a clinical and radiographic 12-month prospective study. *Int J Periodontics Restorative Dent* 2003; 23:313–323.
- Araujo M, Sukekava F, Wennstrom J, Lindhe J. Ridge alternations following implant placement in fresh extraction sockets: an experimental study in the dog. *J Clin Periodontol* 2005; 32:645–652.
- Araujo M, Lindhe J. Dimensional ridge alternations following tooth extraction. An experimental study in the dog. *J Clin Periodontol* 2005; 32:212–218.
- Araujo M, Sukekava F, Wennstrom J, Lindhe J. Tissue modeling following implant placement in fresh extraction sockets. *Clin Oral Implants Res* 2006; 17:615–624.
- Ten Haggeler JMAG, Slot DE, van der Weijden GA. Effect of socket preservation therapies following tooth extraction in non molar regions in human: a systematic review. *Clin Oral Impl Res* 2011; 22:779–788.
- Walsh WR, Morberg P, Yu Y, et al. Response of a calcium sulfate bone graft substitute in a confined cancellous defect. *Clin Orthop Relat Res* 2003; 406:228–236.
- Crespi R, Cappare P, Gherlone E. Magnesium-enriched hydroxyapatite compared to calcium sulfate in the healing of human extraction sockets: radiographic and histomorphometric evaluation at 3 months. *J Periodontol* 2009; 80:210–218.
- Kelly CM, Wilkins RM, Gitelis S, Hartjen C, Watson JT, Kim PT. The use of a surgical grade calcium sulfate as a bone graft substitute: results of a multicenter trial. *Clin Orthop Relat Res* 2001; 382:42–50.
- Deliberador TM, Nagata MJ, Furlaneto FA, et al. Autogenous bone graft with or without a calcium sulfate barrier in the treatment of Class II furcation defects: a histologic and histometric study in dogs. *J Periodontol* 2006; 77: 780–789.
- Coetzee AS. Regeneration of bone in the presence of calcium sulfate. *Arch Otolaryngol* 1980; 106:405–409.
- Nilsson M, Wang JS, Wielanek L, Tanner KE, Lidgren L. Biodegradation and biocompatibility of a calcium sulphate-hydroxyapatite bone substitute. *J Bone Joint Surg* 2004; 86:120–125.
- Cavagna R, Daculsi G, Bouler JM. Macroporous calcium phosphate ceramic: a prospective study of 106 cases in lumbar spinal fusion. *J Long Term Eff Med Implants* 1999; 9:403–412.
- Nery EB, Eslami A, Van Sworl RL. Biphasic calcium phosphate ceramic combined with fibrillar collagen with and without citric acid conditioning in the treatment of periodontal osseous defects. *J Periodontol* 1990; 61:166–172.
- Ransford AO, Morley T, Edgar MA, et al. Synthetic porous ceramic compared with autograft in scoliosis surgery. A prospective, randomized study of 341 patients. *Bone Joint Surg Br* 1998; 80:13–18.
- Mangano FG, Zecca P, Luongo F, Iezzi, G, Mangano C. Single-tooth Morse taper connection implant placed in grafted site of the anterior maxilla: clinical and radiographic evaluation. *Case Rep Dent* 2014; 23:1302–1307.
- Ding C, Qiao Z, Jiang W. Regeneration of a goat femoral head using a tissue-specific, biphasic scaffold fabricated with CAD/CAM technology. *Biomaterials* 2013; 34:6706–6716.

21. Nevins M, Nevins ML, Schupbach P, Kim SW, Lin Z, Kim DM. A prospective, randomized controlled preclinical trial to evaluate different formulations of biphasic calcium phosphate in combination with a hydroxyapatite collagen membrane to reconstruct deficient alveolar ridges. *J Oral Implantol* 2013; 39:133–139.
22. Mangano C, Perrotti V, Shibli JA, Mangano F, Ricci L, Piattelli A, Iezzi G. Maxillary sinus grafting with biphasic calcium phosphate ceramics: clinical and histologic evaluation in man. *Int J Oral Maxillofac Implants* 2013; 28:51–56.
23. Mangano CB, Sinjari B, Shibli JA, et al. Human clinical, histological, histomorphometrical, and radiographical study on biphasic ha-beta-tcp 30/70 in maxillary sinus augmentation. *Clin Implant Dent Relat Res* 2015; 17: 610–618.
24. LeGeros RZ, Parsons JR, Daculsi G, et al. *Ann N Y Acad Sci* 1988; 523:268–271.
25. Avila-Ortiz G, Elangovan S, Kramer KW, Blanchette D, Dawson DV. Effect of alveolar ridge preservation after tooth extraction: a systematic review and meta-analysis. *J Dent Res* 2014; 93:950–958.
26. Horowitz R, Holtzclaw D, Rosen PS. A review on alveolar ridge preservation following tooth extraction. *J Evid Based Dent Pract* 2012; 12:149–160.
27. Arujo MG, Lindhe J. Ridge preservation with the use of Bio-Oss collagen: a 6-month study in the dog. *Clin Oral Implants Res* 2009; 20:433–440.
28. Rothamel D, Schwarz F, Herten M, et al. Dimensional ridge alterations following socket preservation using a nanocrystalline hydroxyapatite paste: a histomorphometrical study in dogs. *Int J Oral Maxillofac Surg* 2008; 37: 741–747.
29. Huynh-Ba G, Pjetursson BE, Sanz M, et al. Analysis of the socket bone wall dimensions in the upper maxilla in relation to immediate implant placement. *Clin Oral Implants Res* 2010; 21:37–42.
30. Spray JR, Black CG, Morris HF, Ochi S. The influence of bone thickness on facial marginal bone response: stage 1 placement through stage 2 uncovering. *Ann Periodontol* 2000; 5:119–128.
31. Vignoletti F, Matesanz P, Rodrigo D, Figuero E, Martin C, Sanz M. Surgical protocols for ridge preservation after tooth extraction. A systematic review. *Clin Oral Implants Res* 2012; 23(Suppl 5):22–38.
32. Fickl S, Zuhr O, Wachtel H, Bolz W, Huerzeler M. Tissue alterations after tooth extraction with and without surgical trauma: a volumetric study in the beagle dog. *J Clin Periodontol* 2008; 35:356–363.
33. Toloue SM, Chesnoiu-Matei I, Blanchard SB. A clinical and histomorphometric study of calcium sulfate compared with freeze-dried bone allograft for alveolar ridge preservation. *J Periodontol* 2012; 83:847–55.
34. Kumari B, Gautam DK, Horowitz RA, Jain A, Mahajan A. An evaluation and comparison of the efficacy of nanocrystalline calcium sulfate bone grafts (NanoGen) and medical-grade calcium sulfate bone grafts (DentoGen) in human extraction sockets. *Compend Contin Educ Dent* 2014; 35:e36–e41.